
Noteworthy Parasites (Apicomplexa, Cestoda, Nematoda, Acari) from Plains Leopard Frog, *Rana blairi* (Anura: Ranidae), from Southern Oklahoma

Chris T. McAllister

Science and Mathematics Division, Eastern Oklahoma State College, Idabel, OK 74745

Lance A. Durden

Department of Biology, Georgia Southern University, Statesboro, GA 30460

Stanley E. Trauth

Department of Biological Sciences, Arkansas State University (Emeritus), State University, AR 72467

Charles R. Bursey

Department of Biology, Pennsylvania State University, Shenango Campus, Sharon, PA 16146

Henry W. Robison

602 Big Creek Drive, Sherwood, AR 72120

Abstract: A single adult plains leopard frog, *Rana blairi*, was collected from Marshall County, Oklahoma, and examined for ecto- and endoparasites. It was found to be infected with an unknown species of *Hepatozoon* and with trypanosomes of three distinct morphologies. This host also harbored a metacestode (*Mesocestoides* sp.) in the liver and mesenteries, a nematode (*Oswaldocruzia pipiens*) in the small intestine, and engorged larval *Hannemania dumni* and *Hannemania hegeneri* chiggers in skin tissue. Here, we provide the first report of hemoparasites from *R. blairi* in Oklahoma, including photomicrographs of the infection. In addition, the chigger *H. hegeneri* is reported from *R. blairi* and Oklahoma for the first time.

Introduction

The plains leopard frog, *Rana blairi* Mecham, Littlejohn, Oldham, Brown, and Brown occurs from western Indiana to southeastern North Dakota and eastern Colorado and south to central and west Texas and further westward to Arizona (Brown 1992; Powell et al. 2016). In Oklahoma, *R. blairi* is primarily found in the central and western parts of the state, including the Panhandle (Sievert and Sievert 2021). It inhabits plains and prairies and generally feeds on various insects, earthworms, and aquatic

snails (Hartman 1906).

Although there is a great deal of ecological and natural history information on *R. blairi* (Smith and Keinath 1985; Brown 1992; Parris 1998; Parris and Semlitsch 1998; Bolek and Janovy 2004), only a moderate amount of studies have documented parasites of this frog. Walton (1929) originally described a nematode, *Raillietnema longicaudata* as *Aplectana longicauda* from hosts identified as northern leopard frogs, *Rana pipiens* (Schreber) from Illinois; however, in his redescription, Baker (1985) doubted the host identification as three species of this complex

with ranges that overlap (including *R. blairi*) occur in Illinois. Therefore, the host species cannot be verified. Brooks (1976) and Brooks and Welch (1976) reported trematodes from *R. blairi* in Nebraska. Bolek and Janovy (2005) found leeches, *Placobdella* (syn. *Desserobdella*) *picta* (Verrell, 1872) on *R. blairi* in Nebraska. Bolek et al. (2009) listed *R. blairi* as a host of the bladder fluke, *Gorgoderina attenuata* (Stafford, 1902) Stafford, 1905. The largest study, to date, on parasites of *R. blairi* was by Goldberg et al. (2000) who examined 73 specimens from Colorado, Kansas, Iowa, and Nebraska. Bolek and Janovy (2007) and Langford et al. (2013) reported *Haematoloechus coloradensis* (Cort, 1915) Ingles, 1932, and two species of lung parasites (*Haematoloechus* and *Rhabdias*) from *R. blairi* from Nebraska, respectively. In another study, Langford and Janovy (2013) reported two species of *Rhabdias* in *R. blairi* from Nebraska. McAllister et al. (2017) reported a chigger mite, *Hannemania dumni* Sambon, 1928, from *R. blairi* from Texas. However, none of these surveys included examination of the blood. Interestingly, the online Aquatic Parasite Observatory at the University of Colorado lists several parasites from *R. blairi* without detailed information or cited literature (<http://www.aquaticparasites.org/hosts/amphibia/anura/ranidae/rana/blairi.php>). We also are unaware of any previous studies of parasites of *R. blairi* from Oklahoma.

Haemogregarines are apicomplexan blood-inhabiting parasites with an obligatory heteroxenous life cycle. They are ubiquitous in all types of vertebrates, including fishes, amphibians, lizards, snakes, turtles, crocodylians, birds, and mammals. However, classification of haemogregarines is problematic when information about the life cycle stages is lacking. Therefore, the basis for taxonomic classification of genera/species of haemogregarines is related to the sporogonic part of the life cycle where sexual reproduction occurs in the hematophagous invertebrate vector (Telford 2009). The inclusion of a molecular approach is an excellent tool that can aid in the identification of these parasites by elucidating their evolutionary relationships.

Here, we document some new host and

distributional records of some parasites of a plains leopard frog from the state, including histological information on the infections/infestations.

Methods

On 22 April 2022, a single adult gravid female *R. blairi* (85 mm snout-vent length) was collected alive by hand from just SE of Willis on the OU road, vicinity of the University of Oklahoma Biological Station (UOBS), Marshall County (33°53'03.732"W, -96°48'58.1472"N). It was anesthetized by immersion in a dilute solution of tricaine methanesulfonate (TMS-222). Orange to red-colored encapsulated chiggers were noted, excised from the skin (abdomen and legs), and placed in 70% (v/v) DNA grade ethanol or with attached tissue in 10% (v/v) neutral buffered formalin (NBF) for histosectioning. They were sectioned at 8 μ m, stained with Pollak stain, and processed per the methods of Presnell and Schreibman (1997). For photomicroscopy, a Nikon Eclipse 600 epifluorescent light microscope with a Nikon DXM 1200C digital camera (Nikon Instruments Inc., Melville, NY) was used. Chiggers in ethanol were cleared in lactophenol, slide-mounted in Hoyer's medium (Walters and Krantz 2009), and identified using Brennan and Goff (1977).

Blood was drawn from the facial musculocutaneous vein of the anesthetized specimen following the methods of Forzán et al. (2012) and collected in an ammonium heparinized (75 mm long) capillary tube. Two separate blood smears were made and fixed briefly in absolute methanol, stained with Wright's-Giemsa stain for 30 min, and rinsed in buffer (pH = 7.0). They were screened initially at 400 \times magnification for extracellular hemoparasites, such as trypanosomes, and at 1000 \times for intraerythrocytic parasites, using a Swift Model M10 light microscope with an in-built digital camera (Commack, New York). Hematozoan parasites were identified to genus based on previous reports of hematozoa infecting other ranid frogs in North America (see McAllister et al. 2020).

The frog was euthanized with a concentrated solution of TMS-222 and a midventral incision was made from the cloaca to throat to expose the viscera. All major organs were examined under a stereomicroscope for parasites, including the entire gastrointestinal tract which was placed in a Petri dish containing 0.9% saline and split lengthwise. When suspected encapsulated tapeworms were observed, they were excised with a small portion of tissue and preserved in 10% NBF and processed for light microscopy (Presnell and Schreibman 1997). For photomicroscopy, a Nikon Eclipse light microscope as described above was used. Two nematodes were found in the small intestine, transferred to a vial containing 70% ethanol, and examined in a drop of glycerol under a coverslip.

We follow Yuan et al. (2016) in the adoption of the genus *Rana* instead of *Lithobates* for North American ranid frogs. Voucher ectoparasites (chiggers) are deposited in the General Ectoparasite Collection in the Department of Biology at Georgia Southern University, Statesboro, GA (accession numbers L-3859A, L-3859B). Slide material, specimens in ethanol, and/or photovouchers were deposited in the Harold W. Manter Laboratory of Parasitology (HWML), University of Nebraska, Lincoln, NE. The voucher host was deposited in the Eastern Oklahoma State College Vertebrate Collection, Idabel, OK.

Results and Discussion

A variety of different protozoan and

metazoan parasites, including two blood-inhabiting parasites, a cestode, a nematode, and two species of ectoparasites were harbored by this single frog. Data are provided on each in an annotated format below.

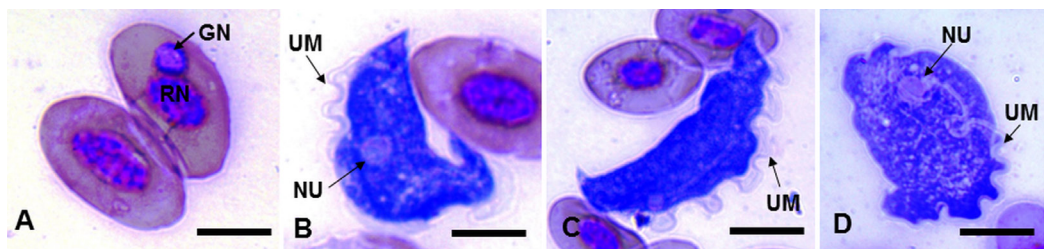
Apicomplexa: Adeleorina: Hepatozoidae

Hepatozoon sp. Miller, 1980 – a single red blood cell (rbc) containing a gamont of an intraerythrocytic hematozoan belonging to an unknown species of the genus *Hepatozoon* (HWML 216905, Fig. 1A) was found. The gamont was spheroidal and the rbc nucleus was non-fragmented. No other erythrocytes were observed with gamonts.

In terms of those species within the family Ranidae Rafinesque, both the American bullfrog, *Rana catesbeiana* (Shaw) and green frog, *Rana clamitans* (Latreille) have been previously reported to harbor *Hepatozoon* spp. from New York and Ontario, Canada, including the latter frog species from Arkansas (see McAllister et al. 2020). To our knowledge, there have been no previous reports of hematozoans from amphibians of Oklahoma. We document the first report of a *Hepatozoon* sp. from *R. blairi* from the state.

Euglenozoa: Kinetoplastea: Trypanosomatida: Trypanosomatidae

Trypanosoma sp. Gruby, 1843 – three distinct morphologies of trypanosomes (“a, b, and c”) were found (HWML 216906, Figs. 1B–D) representing a combined intensity of



Figures 1A–D. Photomicrographs of hematozoan parasites infecting *Rana blairi*. (A) Gamont nucleus (GN) of a *Hepatozoon* sp. and host red blood cell nucleus (RN); scale bar = 10 μ m. (B) *Trypanosoma* sp. (“form a”) showing undulating membrane (UM) and nucleus (NU); scale bar = 10 μ m. (C) *Trypanosoma* sp. (“form b”) showing UM; scale bar = 20 μ m. (D) *Trypanosoma* sp. (“form c”) showing NU and UM; scale bar = 20 μ m. All Wright’s-Giemsa stain.

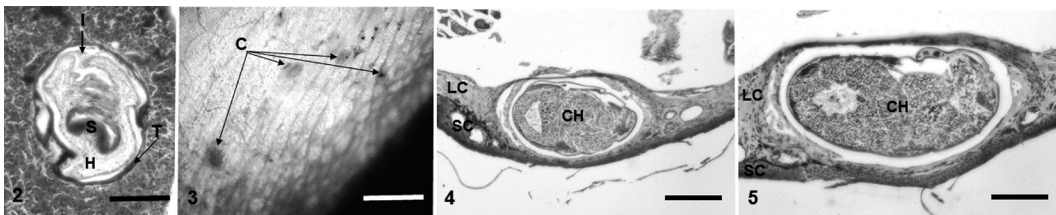
about 3%. McAllister et al. (2020) reported similar morphologies of three trypanosomes from *R. clamitans* from Arkansas. To our knowledge, trypanosomes have not been previously reported from *R. blairi*, but in addition to Arkansas, noted above for green frogs, they have been reported from *R. clamitans* from Louisiana (Southworth et al. 1968), and Ontario, Canada (Barta and Desser 1984). Trypanosomes have the remarkable ability to change their morphology throughout their life cycle, and as such, are considered pleomorphic (Desser 2001). Individual anurans are often infected with multiple morphologies and it is unknown whether these forms represent different taxa or a single pleomorphic species. Therefore, based on morphology alone, species of trypanosomes cannot be identified; however, careful isolation, culturing, and experimental infections of anurans are required to describe and to determine a specific identity (Desser 2001). We document the first report of *Trypanosoma* from *R. blairi* as well as the first amphibian from the state with this hemoparasite.

Cestoda: Cyclophyllidea: Mesocestoididae

Mesocestoides sp. Vaillant, 1863 – numerous metacestodes (tetrathyridia) belonging to the genus *Mesocestoides* were found in the mesenteries and encapsulated in the liver (HWML 216904, Fig. 2). McAllister et al. (1990) examined seven *R. blairi* from Texas for

Mesocestoides but none harbored the tapeworm. However, Goldberg et al. (2000) reported this cestode from *R. blairi*, including one of 18 (6%) individuals from Kansas, four of 16 (25%) in Iowa, and five of 55 (9%) from Nebraska, but no photomicrographs were provided. *Mesocestoides* sp. has been reported from an additional six species of North American ranid frogs from Arkansas, Michigan, New York, Oklahoma, South Dakota, Texas, and Wisconsin (see summary by McAllister et al. 2014). Interestingly, McAllister et al. (2005) reported *Mesocestoides* sp. from two species of spadefoot toads from the same general locality (UOBS) reported herein. In addition, other amphibians from Oklahoma have been reported to harbor *Mesocestoides* sp. (see summary by McAllister et al. 2021).

In the present infection, tetrathyridia possessed characteristic individual features of a single invaginated tetra-acetabulate scolex, a large and deep invagination canal, and a solid hindbody (Fig. 2). None possessed a divided scolex, somatic bud, or any excretory or tegumental anomalies, infrequently reported from tetrathyridia in some aberrant acephalic forms from other hosts (Conn et al. 2011). We document *Mesocestoides* sp. from *R. blairi* in Oklahoma for the first time.



Figures 2–5. Photomicrographs of metazoan parasites of *Rana blairi*. (2) Pollak stained histologic section of *Mesocestoides* sp. tetrathyridia in host-derived fibrotic capsule in liver showing characteristic solid cellular hindbody (H), deep invagination canal (I), tetra-acetabulate scolex (S), and syncytial tegument (T). Note the absence of buds, multiple scoleces, or any other evidence of asexual proliferation. Also note the thin host-derived capsule, normal appearance of hepatic parenchyma, and pigment deposition; scale bar = 200 μ m. (3) Stereoscopic view of four *Hannemania hegeneri* chiggers (C, arrows) encapsulated in host tissue; scale bar = 5 mm. (4) Histosection of single encapsulated *H. hegeneri* (CH) in host tissue, LC (loose connective tissue), stratum corneum (SC); scale bar = 500 μ m. Pollak stain. (5) Higher magnification of a different host-derived capsule showing CH, LC, and SC; scale bar = 250 μ m. Pollak stain.

Nematoda: Strongylida: Molineidae

***Oswaldocruzia pipiens* Walton, 1929** – Two adult specimens (one male, one female) of *O. pipiens* (HWML 118079) were found in the intestinal tract. Goldberg et al. (2000) reported that seven of 18 (22%) *R. blairi* from Kansas harbored this nematode. This roundworm has been previously reported from dwarf American toad, *Anaxyrus americanus charlesmithi* (Bragg), Woodhouse's toad, *Anaxyrus woodhousii* (Girard), *R. catesbeianus*, southern leopard frog, *Rana sphenoccephalus utricularius* (Cope) and Hurter's spadefoot, *Scaphiopus hurterii* Strecker from Oklahoma (Trowbridge and Hefley 1934; Kuntz 1941; Kuntz and Self 1944; McAllister et al. 2005, 2014). We document *O. pipiens* from an Oklahoma *R. blairi* for the first time.

Arthropoda: Acari: Leeuwenhoekiiidae

***Hannemania dunnii* Sambon, 1928** – a single engorged larval chigger was found that matched the description of *H. dunnii*. McAllister et al. (2017) previously reported *H. dunnii* from *R. blairi* from Texas. This chigger is a common ectoparasite of a variety of North American salamanders and frogs, including *Rana* spp. (see Watermolen [2021] for a summary of hosts). Previous reports of *H. dunnii* from the state include specimens from *A. a. charlesmithi* (McAllister and Durden 2014), Woodhouse's toad, *A. woodhousii* (Loomis 1956), Blanchard's cricket frog, *Acris blanchardi* (as *A. gryllus*) (Loomis 1956), and *R. s. utricularis* (as *R. pipiens*) (Loomis 1956). This chigger has been previously reported from amphibian hosts from Alabama, Arkansas, Georgia, Kansas, North Carolina, Oklahoma, Texas, Virginia, and West Virginia (Watermolen 2021).

***Hannemania hegeneri* Hyland, 1956** – eight engorged larval specimens of *H. hegeneri* were taken from *R. blairi*. The type host and locality of *H. hegeneri* is *R. s. utricularius* from Sarasota, Sarasota County, Florida (Hyland 1956). It has also been previously reported from various anuran hosts (*Acris*, *Anaxyrus*, *Hyla* [*Dryophytes*], *Rana* spp.) from Florida, Georgia, and Utah (Watermolen 2021). However, this is the first time *H. hegeneri* has been reported from Oklahoma as well as what we believe to

be the first mixed parasitism of two species of *Hannemania* from a single host.

Chiggers were found encapsulated in a host-derived capsule of *R. blairi* and macroscopically (HWML 216903) appeared as conspicuous red to orange raised bumps, ca. 1 mm in diameter (Fig. 3). Similar to what Hyland (1961) reported for *R. s. utricularius* and the pickerel frog, *R. palustris* (LeConte), a local host immune reaction was produced and the surrounding connective tissue became restructured and an envelope of connective tissue (Figs. 4–5) formed around the chigger. This is the first time histopathology has been reported from an infestation of *H. hegeneri* in *R. blairi*.

In summary, although only a single *R. blairi* was examined for parasites, this study shows that a variety of parasites belonging to widely-different taxonomic groups can be found in one specimen collected from Oklahoma that resulted in novel information. However, for a more meaningful distribution of these and other parasites in *R. blairi*, larger sample sizes are recommended, as well as future surveys that take into account ecological differences in various geographic locales, and especially the abundance and identification of capable vectors for its hematozoan parasites.

Acknowledgments

The Oklahoma Department of Wildlife Conservation issued Scientific Collecting Permit No. 21010166 to CTM, Johnny C. Ray (Kiamichi Technology Center, Idabel, OK) for assistance in collecting, and Drs. Scott L. Gardner and Gabor Racz (HWML) are acknowledged for expert curatorial assistance.

References

- Baker MR. 1985. *Raillietnema longicaudata* (Walton, 1929) n. comb. (Nematoda: Cosmoceridae) from North American frogs. Proc Helminthol Soc Wash 52:76–79.
- Barta JR, Desser SS. 1984. Blood parasites of amphibians from Algonquin Park, Ontario. J Wildl Dis 20:180–189.

- Brennan JM, Goff ML. 1977. Keys to the genera of chiggers of the Western Hemisphere. *J Parasitol* 63:554–566.
- Bolek MG, Janovy J Jr. 2004. *Rana blairi* (plains leopard frog) prey. *Herpetol Rev* 35:262.
- Bolek MG, Janovy J Jr. 2005. New host and distribution records for the amphibian leech *Desserobdella picta* (Rhynchobdellida: Glossiphoniidae) from Nebraska and Wisconsin. *J Fresh Ecol* 20:187–189.
- Bolek MG, Janovy J Jr. 2007. Small frogs get their worms first: The role of nonodonte arthropods in the recruitment of *Haematoloechus coloradensis* and *Haematoloechus complexus* in newly metamorphosed northern leopard frogs, *Rana pipiens*, and Woodhouse's toad, *Bufo woodhousii*. *J Parasitol* 93:300–312.
- Bolek MG, Snyder SD, Janovy J Jr. 2009. Redescription of the frog bladder fluke *Gorgoderina attenuata* from the northern leopard frog, *Rana pipiens*. *J Parasitol* 95:665–668.
- Brooks DR. 1976. Parasites of amphibians of the Great Plains. Part 2. Platyhelminths of amphibians in Nebraska. *Bull Univ Nebraska St Mus* 10:65–92.
- Brooks DR, Welch NJ. 1976. Parasites of amphibians of the Great Plains. I. The cercaria of *Cephalogonimus brevicirrus* Ingles, 1932 (Trematoda: Cephalogonimidae). *Proc Helminthol Soc Wash* 43:92–93.
- Brown LE. 1992. *Rana blairi*. *Cat Amer Amph Rept* 536.1–536.6.
- Conn DB, Galan-Puchades M-T, Fuentes MV. 2011. Normal and aberrant *Mesocestoides* tetrathyridia from *Crocidura* spp. (Soricimorpha) in Corsica and Spain. *J Parasitol* 97:915–919.
- Desser SS. 2001. The blood parasites of anurans from Costa Rica with reflections on the taxonomy of their trypanosomes. *J Parasitol* 87:152–160.
- Forzán MJR, Vanderstichel V, Ogbuah CT, Barta JR, Smith TG. 2012. Blood collection from the facial (maxillary)/musculo-cutaneous vein in true frogs (Family Ranidae). *J Wildl Dis* 148:176–180.
- Goldberg SR, Bursley CR, Platz JE. 2000. Helminths of the plains leopard frog, *Rana blairi* (Ranidae). *Southwest Nat* 45:362–366.
- Hartman FA. 1906. Food habits of Kansas lizards and batrachians. *Trans Kansas Acad Sci* 20:225–229.
- Kuntz RE. 1941. The metazoan parasites of some Oklahoma Anura. *Proc Oklahoma Acad Sci* 21:33–34.
- Kuntz RE, Self JT. 1944. An ecological study of the metazoan parasites of the Salientia of Comanche County, Oklahoma. *Proc Oklahoma Acad Sci* 24:35–38.
- Hyland KE Jr. 1956. A new species of chigger mite, *Hannemania hegneri* (Acarina; Trombiculidae). *J Parasitol* 42:176–179.
- Hyland KE. 1961. Parasitic phase of the chigger mite, *Hannemania hegneri*, on experimentally infested amphibians. *Exp Parasitol* 11:212–225.
- Langford GJ, Janovy J Jr. 2013. Host specificity of North American *Rhabdias* spp. (Nematoda, Rhabdiasidae): Combining field data and experimental infections with a molecular phylogeny. *J Parasitol* 99:277–286.
- Langford GJ, Vhora MS, Bolek MG, Janovy J Jr. 2013. Co-occurrence of *Haematoloechus complexus* and *Rhabdias joaquinensis* in the plains leopard frog from Nebraska. *J Parasitol* 99:558–560.
- Loomis RB. 1956. The chigger mites of Kansas (Acarina, Trombiculidae). *Univ Kansas Sci Bull* 37:1195–1443.
- McAllister CT, Bursley CR, Conn DB. 2005. Endoparasites of the Hurter's spadefoot, *Scaphiopus hurterii* and the Plains spadefoot, *Spea bombifrons* (Anura: Scaphiopodidae), from southern Oklahoma. *Texas J Sci* 57:383–389.
- McAllister CT, Bursley CR, Connior MB. 2017. New host and distributional records for parasites (Apicomplexa, Trematoda, Nematoda, Acanthocephala, Acarina) of Texas herpetofauna. *Comp Parasitol* 84:42–50.
- McAllister CT, Conn DB. 1990. Occurrence of tetrathyridia of *Mesocestoides* sp. (Cestoidea: Cyclophyllidea) in North American anurans. *J Wildl Dis* 26:540–543.

- McAllister CT, Connior MB, Trauth SE. 2014. New host records for *Mesocestoides* sp. tetrathyridia (Cestoidea: Cyclophyllidae) in anurans (Bufonidae, Ranidae) from Arkansas, with a summary of North American amphibian hosts. *J Arkansas Acad Sci* 68:158–162.
- McAllister CT, Durden LA. 2014. New records of chiggers and ticks from an Oklahoma amphibian and reptile. *Proc Oklahoma Acad Sci* 94:40–43.
- McAllister CT, Shannon RP, Fayton TJ, Robison HW. 2020. Hemoparasites (Apicomplexa: *Hepatozoon*; Kinetoplastida: *Trypanosoma*) of green frogs, *Rana clamitans* (Anura: Ranidae) from Arkansas. *J Arkansas Acad Sci* 74:37–40.
- McAllister CT, Trauth SE, Robison HW. 2021. Tetrathyridia of *Mesocestoides* sp. (Cestoda: Cyclophyllidae: Mesocestoididae) from pickerel frog, *Rana palustris* (Anura: Ranidae), with a summary of hosts from Oklahoma. *Proc Oklahoma Acad Sci* 101:96–100.
- Parris, M.J. 1998. Terrestrial burrowing ecology of newly metamorphosed frogs (*Rana pipiens* complex). *Can J Zool* 76:2124–2129.
- Parris MJ, Semlitsch RD. 1998. Asymmetric competition in larval amphibian communities: Conservation implications for the northern crawfish frog, *Rana areolata circumlosa*. *Oecologia* 116:219–226.
- Powell R, Conant R, Collins JT. 2016. Peterson field guide to reptiles and amphibians of eastern and central North America. Boston (MA): Houghton Mifflin Harcourt. 494 p.
- Presnell JK, Schreiber MP. 1997. Humason's animal tissue techniques. 5th ed. Baltimore (MD): Johns Hopkins University Press. 600 p.
- Sievert G, Sievert L. 2021. A field guide to Oklahoma's amphibians and reptiles. 4th ed. Oklahoma City (OK): Oklahoma Department of Wildlife Conservation. 231 p.
- Smith BE, Keinath DA. 1985. Plains leopard frog (*Rana blairi*): A technical conservation assessment [online]. Prepared for the USDA Forest Service, Rocky Mountain Region, Species Conservation Project. Available from: <http://www.fs.fed.us/r2/projects/scp/assessments/plainsleopardfrog.pdf> (Accessed October 15, 2022).
- Southworth GC, Mason G, Seed JR. 1968. Studies on frog trypanosomiasis. I. A 24-hour cycle of parasitemia level of *Trypanosoma rotatorium* in *Rana clamitans* from Louisiana. *J Parasitol* 54:255–258.
- Telford SR. 2009. Hemoparasites of the Reptilia: Color atlas and text. Boca Raton (FL): CRC Press, Taylor and Francis Group. 376 p.
- Trowbridge AH, Hefley HM. 1934. Preliminary studies of the parasite fauna of Oklahoma anurans. *Proc Oklahoma Acad Sci* 14:16–19.
- Walter DE, Krantz GW. 2009. Collection, rearing and preparing specimens. In: Krantz GW, Walter DE, editors. A manual of acarology, 3rd edition. Lubbock (TX): Texas Tech University Press. p. 83–96.
- Walton AC. 1929. Studies on some nematodes of North American frogs. I. *J Parasitol* 15:227–240.
- Watermolen DJ. 2021. Comprehensive catalog of chiggers (Arachnida: Acari) reported from North American amphibians. *Smithson Herpetol Infor Serv* 158:1–37.
- Yuan, Z-Y, Zhou W-W, Chen, X, Poyarkov NA Jr, Chen H-M, Jang-Liaw N-H, Chou W-H, Matzke NJ, Iizuka K, Min M-S, Kuzmin SL, Zhang Y-P, Cannatella DC, Hillis DM, Che J. 2016. Spatiotemporal diversification of the true frogs (genus *Rana*): A historical framework for a widely studied group of model organisms. *Syst Biol* 65:824–842.

Submitted October 31, 2022 Accepted November 22, 2022